



Bridging the Gap Between Compression and Exudate Management in Lower Extremity Wounds

Suzie Ehmann, DPT CWS CLT -LANA (Carolinus HealthCare System - Stanly)

BACKGROUND

Compression is the gold standard for management of edema associated with venous leg ulcers (VLU)¹. Unfortunately, during seven day compression cycles, chronic wound exudate oftentimes leads to maceration of the periwound, degradation of healthy skin, patient discomfort and ultimately prolonged healing times.² Combining a new compression technology, **Fuzzy Wale Compression (FWC)**, with a unique exudate management technology, **Active Fluid Management (AFM)**, has shown improved healing times in previously recalcitrant wounds. Results from "in-vitro" pressure mapping reveal a unique compression profile while five case studies resulted in a healthy peri-wound skin and short time for wound closure.

MATERIALS AND METHODS

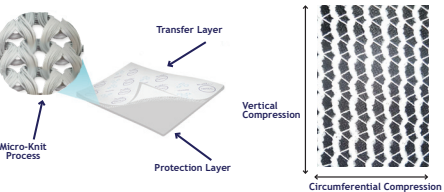
In-vitro Laboratory Testing: Pressure profiles for the FWC technology applied to a **Simulated Leg Model (SLM)** were evaluated. In experiment #1, a pressure sensor was placed between the FWC stockinet and SLM to capture the unique pressure profile. In experiment #2, thermal imaging was used to assess the pressure profile impact of different dressing formats between the FWC and a healthy leg.

Clinical Evaluation: Five patients, ages 58-85, presented to an outpatient lymphedema clinic for management of lower extremity swelling and chronic non-healing wounds. Intervention included a combination of AFM, FWC and additional compression therapy where appropriate. Wound characteristics and measurements were documented.

TECHNOLOGY


AFM technology is a bi-component textile engineered to move exudate through the **Protection Layer** to the **Transfer Layer**, where it is transferred into an absorbent reservoir. The **Micro-Knit Process** creates a capillary action which pulls the exudate up and away from the wound bed providing an optimal environment for wound healing.

The FWC technology is composed of fuzzy longitudinal wales that are connected by Lycra spandex elastic yarns. Fuzzy wales create a unique compression stockinet that compresses just 20% of the skin surface. The non-compressed subcutaneous tissue between the wales has open veins and lymphatics that promote return of edema fluid into the vascular space.




RESULTS

Experiment 1
Compression levels of 10-23 mmHg were recorded between the fuzzy white longitudinal wales and the SLM.

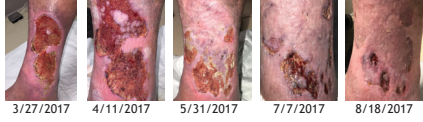

Experiment 2
The use of a thin wound contact layer has minimal impact on the temperature differential between fuzzy longitudinal wales vs a ~4mm foam dressing.



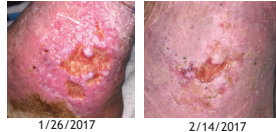Case 1

- 76 year old male with wound medial/lateral aspect of right LE
- PMH: CAD, CVI, HTN, COPD, ambulatory with SPC
- Previous treatment: Unna boot, elastic tubular netting, silver alginate
- Clinical evaluation treatment: AFM → FWC → Layered 4x4 Gauze → ABD Pad → Kling → 2 Layer Cohesive Wrap
- Results: Dressings changed 2x/week for first month, then weekly for one month, then biweekly thereafter. No periwound maceration observed even with biweekly dressing changes. Complete wound closure in ~20 weeks



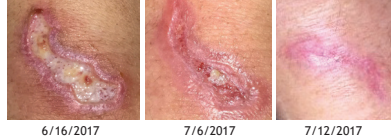Case 2

- 85 year old male wound medial aspect right LE superior to malleoli
- PMH: CVI, HTN, DM, COPD, amb with RW
- Previous treatment: "lite" cohesive 2-layer wrap with silver alginate changed weekly
- Clinical evaluation treatment: AFM → FWC → Layered 4x4 Gauze → Kling → 2 Layer Cohesive Wrap
- Results: Dressings changed 2x/week. No periwound maceration observed with nearly complete wound closure in ~8 weeks



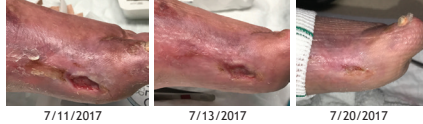Case 3

- 58 year old female with non-healing wound
- PMH: lipedema, obesity, DM
- Previous treatment: honey alginate
- Clinical evaluation treatment: AFM → FWC → Layered 4x4 Gauze → Kling
- Results: Dressings changed 2x/week. Dressings simple enough patient could do themselves. No periwound maceration observed with nearly complete closure in ~8 weeks



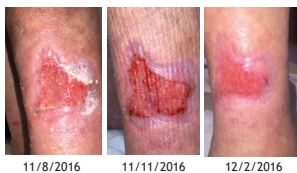Case 4

- 71 year old patient with non-healing ulceration left foot present for >1yr
- PMH: PAD s/p right AKA, RA, DM, w/c dependent
- Previous treatment: angioplasty left LE, compression with Unna boot, 2 layer cohesive "lite", elastic tubular stockinet, multi-component lymphedema wrap, multitude of moist wound therapy including alginate with silver and honey alginate, silver hydrogels, ECM dressings.
- Clinical evaluation treatment: AFM → FWC → Layered 4x4 Gauze → Kling → Multi-component Lymphedema Wrap
- Results: Dressings changed 2x/week. Perimeter of wound stable with no observable maceration. Complete wound closure in ~2 weeks



Case 5

- 64 year old male with h/o bilateral LE ulcerations distal posterior lateral aspect present >6months unresponsive to traditional care
- PMH: RA, CVI, PAD / CVIs/p angioplasty and venous ablation, w/c dependent
- Previous treatment: alginate with silver, honey, foam dressing, elastic tubular stockinet
- Clinical evaluation treatment: Had caregiver use AFM and FWC
- Results: Dressings changed 2x/week. Wound closed in 11 weeks (5 clinic visits) - caregiver performed care.

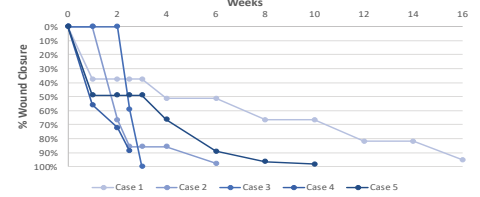
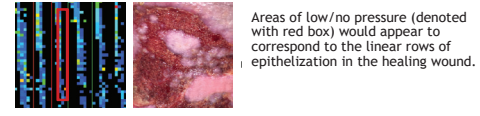


DISCUSSION

Successful wound healing involves adequate circulation and the management of the wound environment and wound exudate. The combination of AFM and FWC addresses each of these.

Chronic wound fluid contains high levels of proteases, pro-inflammatory cytokines and elevated levels of MMPs.³ Prolonged exposure to chronic wound fluid is thought to degrade the extracellular matrix, prolong the inflammatory phase, and degrade periwound tissue with deleterious effects. AFM is designed to manage the wound exudate by pulling it through the protection layer and distributing it across the transfer layer to be absorbed into a secondary dressing. Ease of use is a positive secondary benefit, facilitating wound care when a skilled healthcare provider is not available.

Maximizing venous and lymphatic return without compromising arterial inflow is the goal of compression. The effects of compression discussed in the literature focuses on the positive effects of compression on the macro-circulation of the limb via its direct impact on the venous system.^{1,3-6} The observed linear epithelization mirrors the linear areas of low pressure produced by the FWC, as well as the reduced epibole/improved edge effect seen with the addition of the FWC to the wound care regime. One possible explanation is that the FWC lowers the tissue pressure in areas of the wound bed and along the margins allowing for an enhanced microcirculation in those channels of lower pressure. This micro-circulation provides a favorable environment for epithelial advancement. Taking epithelial advancement as a sign of wound healing, it suggest that this unique type of compression benefits wound healing.³



CONCLUSION

The combination of AFM and FWC demonstrate the ability to effectively manage wound moisture and impact the overall micro-circulatory environment of the wound bed itself. Further scientific investigation regarding the exact mechanism of action is warranted.

References

- O'Donnell TF et al. Management of venous leg ulcers: clinical practice guidelines of the Society for Vascular Surgery and the American Venous Forum. J Vasc Surg. 2014 Aug; 60(2 Suppl):35-59S
- Whitehead F et al. Identifying, managing and preventing skin maceration: a rapid review of the clinical evidence. J Wound Care 2017 April; vol 26, no 4, 159-165
- Lequer DJ et al. Extending the TIME concept: what have we learned in the past 10 years? Int Wound J 2012; 9(Suppl 2):1-19
- Eberhardt RT, Raffetto JD. Chronic venous insufficiency. Circulation 2014 Jul 22; 130(4):333-46.
- MacGregor Lisa. Principles of Compression in venous disease, a practitioner's guide to treatment and prevention of venous leg ulcers. Wounds International. 2015
- Partsch H. Compression therapy of venous ulcers: Hemodynamic effects depend on interface pressure and stiffness. EWMA Journal. 2006, Volume 6(2).

* Outside pressure testing completed by Clemson University Bioengineering